

Case Report

LITHIUM INDUCED DARIER'S DISEASE – A CASE REPORT

Dinesh kumar M K^{1*}, Aswathi T V², Shima K³

¹Department of Psychiatry, Malabar Medical College, Modakkallur, Calicut

²Department of Dermatology, Malabar Medical College, Modakkallur, Calicut

³Department of Pathology, Malabar Medical College, Modakkallur, Calicut

*Corresponding address: dineshmk2010@gmail.com

Submitted online:8/1/2020 Published online:21/2/2020

ABSTRACT

Lithium has been used frequently in the management of Affective disorders for six decades and known to cause dermatological adverse events in the form of Acne, exacerbation of Psoriasis etc. Here we report another dermatological manifestation of Lithium therapy, induction of Darriers disease. Though there are reports of Lithium exacerbating the lesions of Darriers disease, it is rare that the Lithium therapy itself precipitating the emergence of the lesions.

Keywords: Lithium, Bipolar disorder, Darriers disease

INTRODUCTION

Lithium was the first drug discovered for the treatment of mental disorders.¹ Lithium has been the drug of choice in both the management of acute stage and prophylaxis of bipolar disorder, schizoaffective disorder and alcohol dependence.² Lithium has been associated with cardiac, renal and thyroid adverse effects. Dermatological adverse effects of lithium in the form of acneiform and follicular eruptions and exacerbation of psoriasis are quite common.³ Lithium therapy has been known to exacerbate the lesions of the Darriers disease(DD). The case report presented below suggests that Lithium can induce the dermatological condition Darriers disease(DD).

CASE REPORT

A 24-year-old patient who has been on regular treatment for bipolar disorder for ten years was admitted with increased talk, hyperactivity and irritability for a month. She had undergone a course of Electro Convulsive Therapy (ECT) and was on Sodium Valproate 500mg twice daily, Olanzapine 10 mg twice daily and Lorazepam 2mg at bedtime. The patient was switched over to Lithium 400mg, Clozapine 50mg and Risperidone 4mg twice daily. A week later, the patient presented with red, raised lesions over the face, neck and upper trunk. The dermatologist diagnosed the condition as acneiform eruption (due to lithium) with

Please cite the article as: MK Dineshkumar, TV Aswathi, K Shima. Lithium induced darier's disease- a case report. Kerala Journal of Psychiatry 2019; 32(2):

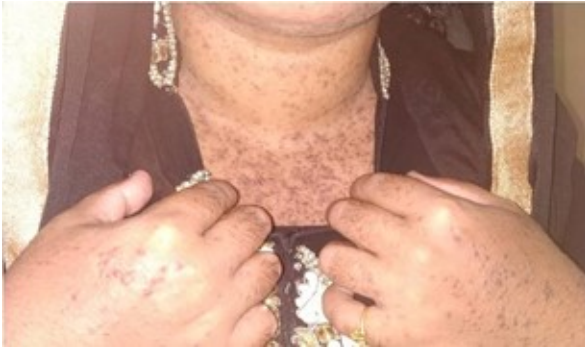

Figure.1. Hyperkeratotic dirty looking brown to black papules over the neck and dorsum of fingers

seborrheic dermatitis and the patient was given benzyl peroxide gel and calamine lotion for topical application. Her psychiatric conditions improved considerably, and she was discharged. After 3 weeks, during her follow up in the outpatient, it was found she had extensive skin manifestations for which review by the dermatologist was considered. On examination, there was hyperkeratotic brown to black papules of size 0.5×0.5 cm over the scalp margins, face, neck, upper

chest, bilateral axilla. Some lesions over the neck and retro-auricular area were greasy and dirty looking. Fingernails showed fragile, longitudinal splits with V-shaped nicking. Diagnosis of DD was considered. Lithium was stopped and proceeded with a skin biopsy. The patient was maintained on topical calamine lotion. The patient improved clinically. Her father had similar lesions, and the biopsy was consistent with DD.

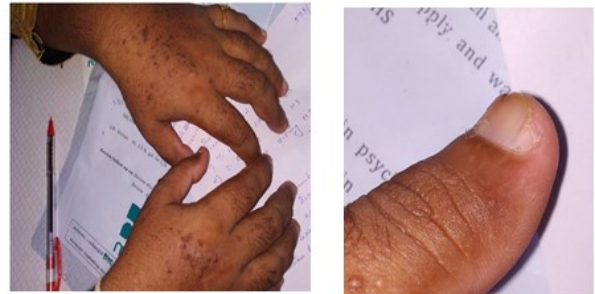

Figure.2. Fragile fingernails with longitudinal splitting and V-shaped nicking over the thumb

Histopathological Findings

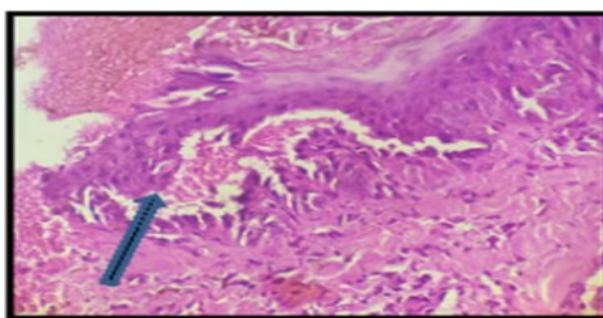


Figure.3

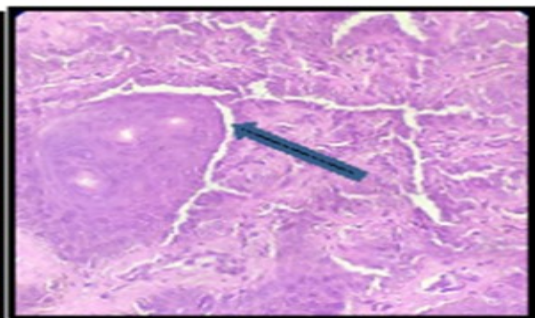


Figure.4

Section from skin-epidermis shows hyperkeratosis and acanthosis. Few foci shows acantholysis with suprabasal cleft and dyskeratotic cells (corps ronds) having basophilic nuclei and perinuclear halo (figure.3). Dermal papillae seen lined by single layer of cells forming villi. Proliferation of basal cells seen as long cords which are separated by narrow lacunar spaces. Similar changes are also seen surrounding hair follicles (figure.4). Dermis shows mild periappendageal lymphocytic infiltrate.

DISCUSSION

The dermatological condition described by Darier is characterized by hyperkeratotic papules distributed over seborrhic body area, nail changes, mucosal lesions, palmar keratosis and papular lesions on the foot and hand. The disease prevalence varies from 1 to 3 per lakh population. The condition is otherwise known as Keratosis Follicularis. DD is an inherited autosomal dominant entity with mutation of gene ATP2A2, which is located on the 12q23-q24.1 chromosome.⁴ The gene affects the function of an enzyme SERCA2. This enzyme has a role in intracellular Ca²⁺ signalling which eventually leads to defects in the cell to cell adhesion. Dd in the majority of patients has mild presentation and prognosis is good. In some of the patients, it has a severe manifestation.

It has been reported in a study that the lifetime prevalence of mood disorders is higher than in the normal population.⁵ The study reveals that the lifetime prevalence of mood disorders is 50%; two-thirds of the patients suffer from depression and about 5% per cent bipolar disorder. The study also found high suicidal ideations (31%) in patients suffering from DD. Previous studies have also reported psychiatric disorders in the form of seizures and mental retardations.⁶ Family of patients suffering from DD have been known to have comorbid mood disorders. The frequent association of psychiatric disorders in DD has been a matter of interest and the association of the concerned gene mutations as a factor causing Mood disorders. There is evidence that a susceptibility gene is located near the DD gene.^{7,8}

Lithium is reported to cause dermatological adverse effects in 45% of patients. The common presentation being acneiform and psoriasiform eruptions.⁹ Lithium has effects in the signal transduction pathways. Lithium reduces the levels of cAMP. cAMP pathways have a role in keratinocyte proliferation. When cAMP levels are lowered, it leads to epidermal proliferation.¹⁰ As the nervous system and the skin share a common ectodermal origin, the adverse effect could be related. Moreover, lithium has its effect on the ATP2A2 gene itself and reduces its functionality which leads to the defects in cell adhesion and keratinocyte proliferation.¹¹

CONCLUSION

Lithium therapy is often associated with dermatological adverse effects. The above case reports exacerbation of the dermatological manifestations of DD. There is a high prevalence of affective disorders in DD and may require psychotropic medications including lithium, to manage their illness. Hence it is essential to be aware of this adverse effect in planning treatment for patients suffering from DD.

Financial support and sponsorship

Nil.

Conflicts of interest

There are no conflicts of interest.

REFERENCES

1. Cade JF. Lithium salts in the treatment of psychotic excitement. *Med J Aust.* 1949;2(10):349-52
2. Malhi GS, Tanious M, Das P Berk M. The science and practice of lithium therapy. *Aust N Z J Psychiatry.* 2012;46(3):192-211
3. Callaway CL, Hendrie HC, Luby ED. Cutaneous conditions observed in patients during

- treatment with lithium. *Am J Psychiatry*.1968; 124(8):1424-5.
4. Sakuntabhai A, Ruiz-Perez V, Carter S, Jacobsen N, Burge S, Monk S et al. Mutations in ATP2A2, encoding a Ca²⁺ pump, cause Darier disease. *Nat Genet* 1999; 21(3): 271-7.
 5. Gordon-Smith K, Jones LA, Burge SM, Munro CS, Tavadia S, Craddock N. The neuropsychiatric phenotype in Darier disease. *Br J Dermatol*. 2010;163(3):515-22.
 6. Getzler N, Elint A. Keratosis follicularis. A study of one family. *Arch Dermatol* 1966; 93(5):545-9.
 7. Jacobsen NJ, Lyons I, Hoogendoorn B, Burge S, Kwok PY, O'Donovan MC et al. ATP2A2 mutations in Darier's disease and their relationship to neuropsychiatric phenotypes. *Hum Mol Genet* 1999; (9):1631-6.
 8. Jones I, Jacobsen N, Green EK, Elvidge GP, Owen MJ, Craddock N. Evidence for familial cosegregation of major affective disorder and genetic markers flanking the gene for Darier's disease. *Mol Psychiatry* 2002; 7:424-7.
 9. Yeung CK, Chan HH. Cutaneous Adverse Effects of Lithium. *Epidemiology and Management*. *Am J Clin Dermatol* 2004; 5 (1): 3-8
 10. DiGiovanna J, Aoyagi T, Taylor J, Halprin K. Inhibition of epidermal adenylyl cyclase by lithium carbonate. *J Invest Dermatol* 1981; 76(4):259-63.
 11. Süle N, Tészás A, Kálmán E, Szigeti R, Attila Mészáros A, Kellermayer R. Lithium suppresses epidermal SERCA₂ and PMR₁ levels in the rat. *Pathol Oncol Res*. 2006; 12:234-6.